

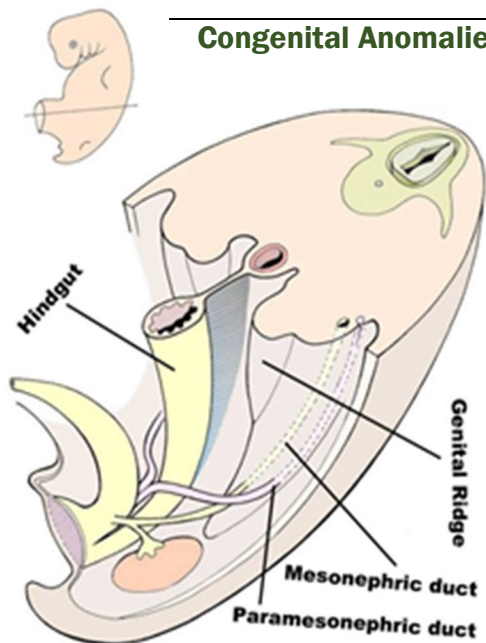
# بسم الله الرحمن الرحيم

Embryology of the Genital Tract: عنوان المحاضرة:

11/2/2013 تاريخ المحاضرة:

المحاضر: د. هاشم فارس

Embryology of the Genital Tract: الـ Development والـ Congenital Anomalies



## الـ Development:

لو أخذنا Cross Section في embryo عمره 7-8 weeks

- 1-Genital Ridge ► Ovaries (Testis in male)  
(Descend to the pelvic brim by the gubernaculum)
- 2-Mesonephric duct ► Wolffian duct, in absence of testosterone It becomes Rudimentary \*\*If Remnant persists → Epooophon
- 3-Paramesonephric duct ► Müllerian ducts gives rise to:  
Fallopian tubes, Uterus, Cervix and upper  $\frac{2}{3}$  of the Vagina  
\*\*Lower  $\frac{1}{3}$  develop from urogenital sinus

## الـ Congenital Anomalies:

### A- Congenital Anomalies of the Ovary:

- 1-Aplasia: متكونش خالص Rare
- 2-Streak gonads: replaced by fibrous tissue
- 3-Chromosomal Abnormalities e.g. Turner syndrome

### B- Congenital Anomalies of the Müllerian duct:

- 1-Aplasia: NO (Fallopian tubes, Uterus, Cervix and upper  $\frac{2}{3}$  of the Vagina) only (Blind Vaginal Pouch)

- بتيجي البنت تشتكي بـ Primary Amenorrhea

- نفرق بينها وبين الـ Other ovarian anomalies إن البنت بيظهر عليها الـ Secondary Sexual Characters بينما لو المشكلتة في الـ Ovary مش هتظهر

### 2-Mal-Union (Improper Fusion):

- a-Arcuate uterus: mal-fusion of the uppermost part of the duct of the middle third (fundal depression)
- b-Bicorps Unicollis: 2 bodies of the uterus with single cervix and vagina
- c-Bicorps Bicollis: 2 Uteruses and 2 Cervixes and single vagina
- d-Double System (Uterus didelphys): 2 x (uterus, cervix, vagina)
- e-Bicornuate Uterus: fusion process of the upper part of the ducts while lower part is normal
- f-Septate Uterus: as Bicornuate but the Serosal lining is fused

### \*\*Complications of Bicornuate Uterus:

- 1-Menorrhagia
- 2-Infertility
- 3-Dysmenorrhea
- 4-Abortion if get pregnant d.t habitual abortion
- 5-Preterm Labour if pregnancy conitnued

### \*\*Causes of Habitual Abortion (Recurrent):

- 1-Chromosomal Abnormalities
- 2-Antiphospholipid Antibody Syndrome (Immunological)
- 3-Uterine malformation

**3-Uncornuate Uterus:** One Müllerian duct is formed and the other one isn't  
\*\* may the other tube dosen't vanish completely leaving **RUDIMENTARY** horn →  
The risk of **ECTOPIC** pregnancy → Rupture

**C-Congenital Anomalies of the Vagina:**

- 1-Failure of Canalization
- 2-Longitudinal/Transverse Vaginal Septum
- 3-Imperforate Hymen

**\*\*Complications of Imperforate hymen:**

- 1-Primary Amenorrhea
- 2-Hematocorpus /Hematometrium /Hematosalpnix /Peritoneal Irritation
- 3-Cyclic Lower Abdominal Pain
- 4-Pelvi-Abdominal mass

